Available online at www.sciencedirect.com

ScienceDirect

journal homepage: www.elsevier.com/locate/jasi

Case Report

A hepatomesenteric trunk, in association with left gastric and splenic arteries arising independently from the abdominal aorta: A case report using MDCT angiography

Nicoleta Iacob [a,e], *Ana Pureca* [b,e], *Olga Belic* [c], *Petru Matusz* [d,*]

[a] *Neuromed Diagnostic Imaging Centre, Department of Anatomy, "Victor Babes" University of Medicine and Pharmacy, Timisoara, Romania*
[b] *Department of Anatomy, "Victor Babes" University of Medicine and Pharmacy, Timisoara, Romania*
[c] *Department of Anatomy, "Nicolae Testemitanu" University of Medicine and Pharmacy, Chisinau, Republic of Moldova*
[d] *Professor, Department of Anatomy, "Victor Babes" University of Medicine and Pharmacy, 2, Eftimie Murgu Square, 300041 Timişoara, Romania*

ARTICLE INFO

Article history:
Received 20 November 2013
Accepted 23 July 2014
Available online 22 August 2014

Keywords:
Hepatomesenteric trunk
Left gastric artery
Splenic artery
Anatomic variants
Multidetector computed tomographic (MDCT) angiography

ABSTRACT

We present a case of a 73-year-old male with peripheral vascular disease of the lower limbs, who on shown MDCT angiography, to have a hepatomesenteric trunk (HMT), and left gastric artery (LGA) and splenic artery (SpA) arising independently from the abdominal aorta (AA), and with additional right renal arteries. The HMT with a length of 5 mm (with an aspect of a common stem origin of common hepatic artery (CHA) and superior mesenteric artery (SMA) arose from the anterior wall of the AA at the level of upper one-third of the L2 vertebral body. The CHA originating from the superior part of the right edge of the HMT, have an ascendent path in front of AA, and finally fork in gastroduodenal artery and hepatic artery proper. With a descending path the SMA across the left renal vein, uncinate process, and inferior part of the duodenum (D3) made an aortomesenteric angle of 61°. The aortomesenteric distance at the level of the L3 vertebral body was 51 mm. The present case is only the 13th reported HMT in association with an independently arising LGA and SpA from the AA, the first case report with this condition using MDCT angiography. Knowledge of the variations in origin and distribution of the HMT is important for planning and performing procedures such as duodenopancreatectomy, liver transplantation, and chemoembolization of the pancreas and hepatic tumors.

* *Corresponding author*. Tel.: +40 256 433 638; fax: +40 356 819 639.
E-mail address: matusz@umft.ro (P. Matusz).
[e] Nicoleta Iacob and Ana Pureca contributed equally to this work.
http://dx.doi.org/10.1016/j.jasi.2014.07.001

1. Introduction

Usually, the celiac trunk (CT) divides into the following three branches: left gastric artery (LGA), common hepatic artery (CHA), and splenic artery (SpA).[1–3] Anatomic variations of the CT and superior mesenteric artery (SMA) are frequent and included many types and forms. Only Song et al using radio-imaging procedures reported 12 cases of hepatomesenteric trunk (HMT) associated with an independently arising LGA and SpA from AA. The aim of the current study was to document the presence of an HMT in association with an independently arising LGA and SpA from the AA.[4] After our knowledge this is the first of which highlighted by MDCT angiography and presenting images of this variation. Cases such as these highlight the importance of having knowledge of the anatomic variations involving the arterial supply of the abdominal viscera.

2. Case report

We report a 73-year-old male with a 40-year history of smoking and peripheral vascular disease of the lower limbs for 12 years. The clinical examination was completed with multidetector computed tomograph (MDCT) angiography (for mapping of the extent and location of arterial disease, and to highlight any associated or concomitant lesions or variations). Using MDCT angiography (64-slice MDCT system; SOMATOM Sensation, Siemens Medical Solutions, Forchheim, Germany), the patient was shown to have, independently of the vascular lesions of the lower limbs, two right additional renal arteries, the presence of an HMT, and the LGA and SpA arose independently from the abdominal aorta (AA) (Fig. 1A–D). The HMT with a length of 5 mm (with an aspect of a common stem origin of CHA and SMA) arose from the anterior wall of the AA at the level of upper one-third of the L2 vertebral body. The

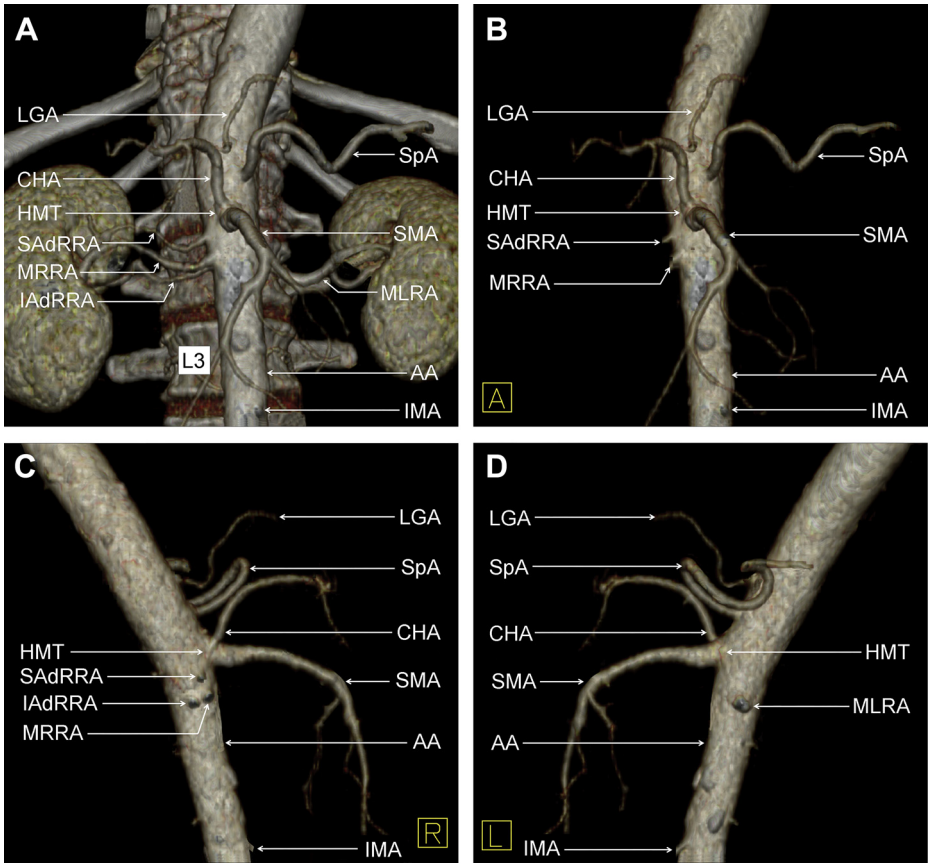

Fig. 1 – MDCT angiography of the abdominal aorta and the kidneys. The volume rendering technique (VRT) images of the abdominal aorta shows the presence of the hepatomesenteric trunk in association with independent origin of left gastric artery and splenic artery, and with the presence of right, left main renal arteries, superior and inferior additional right renal arteries. Anterior volume rendered 3D image (A) shows the relations of the abdominal aorta, right and left kidneys, hepatomesenteric trunk, left gastric artery, splenic artery and renal arteries, with the skeletal structures. Anterior (B), lateral right (C) and lateral left (D) volume rendered 3D images shows the abdominal aorta with the origin of the left gastric artery, splenic artery, hepatomesenteric trunk and the origin of the renal arteries (main and additional), after substraction of the skeletal structures. LGA – left gastric artery; SpA – splenic artery; CHA – common hepatic artery; SMA – superior mesenteric artery; HMT – hepatomesenteric trunk; AA – abdominal aorta; IMA – inferior mesenteric artery; MRRA – main right renal artery; SAdRRA – superior additional right renal artery; IAdRRA – inferior additional right renal artery; MLRA – main left renal artery.

CHA originating from the superior part of the right edge of the HMT, with a length of 54.7 mm have an ascendent path in front of AA, and finally fork in gastroduodenal artery and hepatic artery proper. The latest continues the direction of CHA and forking in left and right branch. With an endoluminal diameter at the origin of 9.0 mm, the SMA had a length of 55.2 mm (to the point of origin of the inferior pancreaticoduodenal artery).

The descending path of the SMA across the left renal vein, uncinate process, and inferior part of the duodenum (D3) (Fig. 1C and D) made an aortomesenteric angle of 61°. The aortomesenteric distance at the level of the L3 vertebral body was 51 mm.

3. Discussion

3.1. *Classification*

Eaton describes for the first time, in his classification of CT branching pattern variation, the presence of HMT and gastrosplenic trunks.[5] Based on 252 anatomic dissection, Adachi proposed a detailed classification of the branching pattern of the CT and SMA, and described 6 types of anatomic variations with 28 forms: (i) hepatogastrosplenic trunk (CT); (ii) hepatosplenic trunk; (iii) hepatosplenomesenteric trunk; (iv) celiacomesenteric trunk (CMT); (v) gastrosplenic in association with HMT; (vi) gastrosplenic trunk in association with replaced common hepatic artery from SMA. In this classification, the HMT is described only in association with the gastrosplenic trunk (Adachi type V).[6]

Based on Tandler's hypothesis, in that the retention or disappearance of some roots of the ventral segmental arteries and some parts of the longitudinal anastomosis leads to the appearance of numerous variations of branching of the CT and SMA.[7]

Morita in 1935 classified the variational pattern of the CT and SMA, and suggested 5 types and 15 forms (5 types with 5 forms for CT and 4 types with 10 forms for CMT).[8] For the CMT Morita describes 4 types depending on the number of arteries that arise from the CMT: (i) with four arteries (hepatogastrosplenomesenteric trunk – CMT); (ii) with three arteries (hepatosplenomesenteric, hepatogastromesenteric and gastrosplenomesenteric trunks); (iii) with two arteries arising from a common trunk (HMT, gastromesenteric, splenomesenteric trunks); and (iv) with the presence of two trunks from each of the two arising arteries (gastroplenic in association with HMT, hepatosplenic in association with gastromesenteric, and hepatogastric in association with splenomesenteric trunks).[8] This classification suggests for the first time, the HMT in association with an independently arising LGA and SpA (Type III').

3.2. *Embryology*

According with the Tandler's hypothesis, in appearance of the HMT in association with the LGA and SpA arising independently from the AA, the longitudinal anastomoses regressed between the 10th–12th ventral segmental arteries and maintained their position between the 12th–13th ventral

Table 1 – Incidence of different types of celiac trunk (CT) and celiacomesenteric trunk (CMT) reported in large series using different methodologies.

Author	[a] Eaton[5]	[b] Lipsutz[10]	[c] Adachi[6]	[e] Chen et al[11]	[f] Song et al[4]			
Year	[1917]	[1917]	[1928]	[2009]	[2010]			
Method of examination	Anatomical dissection	Anatomical dissection	Anatomical dissection	Anatomical dissection	Radioimagistic procedures	**Total**	Anatomical dissection	Radioimagistic Procedures
No. Subjects (100%)	206 (100%)	83 (100%)	252 (100%)	974 (100%)	5002 (100%)	6517 (100%)	1515 (23.25%)	5002 (76.75%)
Hepatogastrosplenic trunk	187 (90.78)	61 (73.49)	221 (87.70)	875 (89.84)	4457 (89.10)	5801 (89.01)	1344 (20.62)	4457 (68.39)
Hepatosplenic trunk & LGA & SMA	9 (4.37)	11 (13.26)	16 (6.35)	43 (4.41)	221 (4.42)	300 (4.60)	79 (1.21)	221 (3.39)
Hepatosplenomestenteric trunk & LGA			3 (1.19)	7 (0.72)	34 (0.68)	44 (0.68)	10 (0.16)	34 (0.52)
Celiacomesenteric trunk			6 (2.38)	7 (0.72)	53 (1.06)	66 (1.01)	13 (0.20)	53 (0.81)
Hepatomesenteric & Gastrosplenic trunks	9 (4.37)		1 (0.40)	34 (3.49)	132 (2.64)	176 (2.70)	44 (0.67)	132 (2.03)
Gastrosplenic trunk & Right hepatic Artery from SMA	1 (0.48)		5 (1.98)			6 (0.09)	6 (0.09)	
Gastrosplenic & CHA & SMA		5 (6.02)		5 (0.51)	11 (0.22)	21 (0.33)	10 (0.16)	11 (0.17)
Hepatogastric & SpA & SMA		6 (7.23)		3 (0.31)	1 (0.02)	10 (0.15)	9 (0.14)	1 (0.01)
Hepatomesenteric & LGA & SpA					**12 (0.24)**	**12 (0.19)**		**12 (0.19)**
Others					81 (1.62)	81 (1.24)		81 (1.24)

segmental arteries.[7] The root of the 12th ventral segmental artery also regresses. The first ventral segmental artery becomes the LGA and the second ventral segmental artery becomes the SpA. Also, the third and fourth ventral segmental arteries connected from the remaining inferior part of the longitudinal anastomosis to become the HMT. In this case, the HMT with a length of 5 mm (and an aspect of a common stem origin of CHA and SMA) in association with the LGA and SpA arising independently from the anterior wall of the AA, suggests the association of two different mechanisms: (i) complete regression of the longitudinal anastomosis with the independent origin from AA of the four ventral segmental arteries (characteristic aspect for absent CT)[9]; (ii) convergence with fusion in a common stem origin of the CHA and SMA.

3.3. *Anatomic variations and clinical implications*

Of 10,750 anatomic dissections, radioimaging procedures and surgical and transplantation procedures from 19 studies revealed the complete CMT in 0.68% of cases; and incomplete CMT in 1.75% of cases.[9]

Of 6517 cases from 5 studies (Table 1),[4–6,10,11] the hepatosplenomestenteric trunk in association with the independent origin of the LGA in 0.68% of cases, and the presence of HMT in association with the independently arising LGA and SpA from the AA was revealed in 0.19% of cases in one study. This last type corresponded to type III' of the Morita classification.[8] Analysis of four anatomical studies from 1523 cases[9] have not highlighted in any way the presence of the HMT in association with independent origin from the AA of the LGA and SMA.[5,6] On 5002 radioimaging procedures the presence of the HMT in association with independent origin of the LGA and SMA was found in 0.24% of cases.[4] It is obvious that the order of sensitivity of the HMT in association with an independent origin of the LGA and SMA recognition was: radioimaging procedures and anatomical dissection, with a prevalence of 0.24%, and 0%, respectively.

Usually, the acute aortomesenteric angle ranges from 25° to 60°[12] and the aortomesenteric distance is 10–28 mm.[13] Any factor decreasing the aortomesenteric angle and distance to 6°–16° and 2–8 mm respectively,[14] will result in external compression or occlusion of the duodenum and potentially the SMA syndrome (Wilkie's syndrome). In our case, the aortomesenteric angle of 61° and maximum distance of 51 mm at the level of the L3 vertebral body was due to a large uncinate process of the pancreas.

4. Conclusions

The present case is only the 13th reported HMT in association with an independently arising LGA and SpA from the AA, the first case report with this condition using MDCT angiography.

In conclusion, this study presents a very rare case, and knowledge of the variations in origin and distribution of the HMT is important for planning and performing procedures such as duodenopancreatectomy, liver transplantation, and chemoembolization of the pancreas and hepatic tumors.

Conflicts of interest

All authors have none to declare.

REFERENCES

1. Hulsberg P, Garza-Jordan Jde L, Jordan R, et al. Hepatic aneurysm: a review. *Am Surg*. 2011;77(5):586–591.
2. Sehgal G, Srivastava AK, Sharma PK, et al. Morphometry of the celiac trunk: a multidetector computed tomographic angiographic study. *JASI*. 2013;62(1):23–27.
3. Venieratos D, Panagouli E, Lolis E, et al. A morphometric study of the celiac trunk and review of the literature. *Clin Anat*. 2013;26(6):741–750.
4. Song SY, Chung JW, Yin YH, et al. Celiac axis and common hepatic artery variations in 5002 patients: systematic analysis with spiral CT and DSA. *Radiology*. 2010;255:278–288.
5. Eaton PB. The coeliac axis. *Anat Rec*. 1917;13:369–374.
6. Adachi B. *Das Arteriensystem der Japaner. Band II. Kaiserlish-Japanischen Universität zu Kyoto*. Kyoto: Maruzen Publishing Co.; 1928:18–71.
7. Tandler J. Über die Varietaten der Arteria coeliaca and deren Entwicklung. *Mat Hefte*. 1904;25:473–500.
8. Morita M. Reports and conception of three anomalous cases in the area of the celiac and the superior mesenteric arteries. *Igaku Kenkyu*. 1935;9:1993–2006.
9. Matusz P, Miclaus GD, Ples H, et al. Absence of the celiac trunk: case report using MDCT angiography. *Surg Radiol Anat*. 2012;34:959–963.
10. Lipshutz B. A composite study of the coeliac axis artery. *Ann Surg*. 1917;65:159–169.
11. Chen H, Yano R, Emura S, et al. Anatomic variation of the celiac trunk with special reference to hepatic artery patterns. *Ann Anat*. 2009;191:399–407.
12. Neri S, Signorelli SS, Mondati E, et al. Ultrasound imaging in diagnosis of superior mesenteric artery syndrome. *J Intern Med*. 2005;257:346–351.
13. Merrett ND, Wilson RB, Cosman P, et al. Superior mesenteric artery syndrome: diagnosis and treatment strategies. *J Gastrointest Surg*. 2009;13:287–292.
14. Mandarry MT, Zhao L, Zhang C, et al. A comprehensive review of superior mesenteric artery syndrome. *Eur Surg*. 2010;42:229–236.