Available online at www.sciencedirect.com

ScienceDirect

journal homepage: www.elsevier.com/locate/jasi

Original Article

# Morphological maturation of the hippocampus during 2nd and 3rd trimester in human fetus: An immunocytochemistry study

*Shilpi Garg* [a], *J.M. Kaul* [b], *Sabita Mishra* [c,*], *Neelam Vasudeva* [d]

[a] *Senior Resident, Department of Anatomy, Maulana Azad Medical College, New Delhi, India*
[b] *Director Professor, Department of Anatomy, Maulana Azad Medical College, New Delhi, India*
[c] *Professor, Department of Anatomy, Maulana Azad Medical College, New Delhi, India*
[d] *Director Professor and Head, Department of Anatomy, Maulana Azad Medical College, New Delhi, India*

ARTICLE INFO

*Article history:*
Received 25 June 2014
Accepted 12 November 2014
Available online 5 December 2014

*Keywords:*
Ventricle zone
Intermediate zone
Hippocampal plate
Marginal zone
Pyramidal cells

ABSTRACT

*Introduction:* Hippocampus is an important component of limbic cortex controlling the activities necessary for survival of animals including procuring of food, eating and emotional behavior. In view of increasing incidence of various disorders like Alzheimer, temporal lobe epilepsy, the structure and development of this region was studied to see its morphological maturation.

*Methods:* In our study ten aborted fetuses from 14 to 30 weeks of gestation were procured from Department of Obstetrics and Gynecology, LN hospital after obtaining ethical clearance. For each gestation age tissue was stained with cresyl violet and Haematoxylin & Eosin to see the normal morphology and immunostaining of the sections was done for the expression of NCAM (Neuronal cell adhesion molecule).

*Results:* Subparts of hippocampus were identified at 14 weeks of gestation. Various fetal zones including ventricle zone, intermediate zone, hippocampal plate and marginal zone were identified. At 20 weeks well differentiated pyramidal cells were seen in hippocampal plate region. At 28 weeks of gestation hippocampus had attained almost mature appearance. NCAM expression was seen in all the fetal zones though staining intensity was more in ventricular zone and hippocampal plate.

*Discussion:* As the age advances ventricular zone thinning occurs, cells become more differentiated. More intense NCAM expression in ventricular zone and granule cell layer of dentate gyrus indicated more cell differentiation in those layers.



* *Corresponding author*. Tel.: +91 9968604206 (mobile).
E-mail address: sabitamishra12@gmail.com (S. Mishra).
http://dx.doi.org/10.1016/j.jasi.2014.11.009

## 1. Introduction

Hippocampus is a part of limbic lobe emerging from the medial wall of the temporal lobe.[1] It controls the activities necessary for survival of the animals including procuring of food, eating and emotional behavior.[2] Hippocampal formation includes dentate gyrus, hippocampus proper, and subicular complex. According to histological point of view, hippocampal cortex has only three fundamental layers. These are the polymorphic layer, pyramidal layer and molecular layer. The most characteristic layer of hippocampal formation is the stratum pyramidalis consisting of large and small pyramidal and Golgi-type 2 cells.[1] Dentate gyrus consists of three layers molecular layer, granular layer and polymorphic layer.[1] The primordium of the hippocampus is the first part of cerebral cortex to develop. It arises by migration of cells from the mantle zone in the dorsomedial part of the wall of the hemisphere into the overlying marginal zone. When the hemisphere expands caudally and ventrolaterally to form the temporal lobe, the hippocampus follows the line of cerebral growth and appears on the medial wall of the hemisphere as a curved area, which lies parallel to the choroidal fissure separating it from the neopallium. The line of projection of the hippocampus in to the ventricle is marked on the surface by hippocampal fissure which forms an arch parallel to the choroidal fissure.[3] The hippocampus pre neurons or neuroblasts are originated in germinal matrix lining the ventricles. These cells migrated both radially along radial glial fibrils and tangentially assumed their position in cortical plate in an inside out gradient and established dendritic arborization and synaptic contact once they have stopped migrating, apoptosis ensued for cells that failed to establish adequate synaptic contact.[4] The hippocampal neuroepithelium consists of three morphogenetically discrete components – the Ammonic neuroepithelium, the primary dentate neuroepithelium, and the fimbrial glioepithelium – and that these are the discrete sources of the large neurons of Ammon's horn, the smaller granular neurons of the dentate gyrus, and the glial cells of the fimbria.[5] Decreased neurogenesis accompanied by reduced immunoreactivity for polysialylated neural cell adhesion molecule, a molecule that is involved in migration and process elongation of developing neurons. The decline in neurogenesis was related to decreasing proliferation of granule cells precursors.[6] NCAMs play an important role in development of nervous system. They are surface glycol proteins and implicated in stereotyped migration of neurons to specific regions. Development of hippocampus gained importance recently, as it was seen that stress, opiate abuse and seizures influenced the rates of cell proliferation and differentiation of new neurons in the dentate gyrus of developing hippocampus.[7] During development four fundamental embryonic zones i.e ventricle zone, intermediate zone, hippocampal plate and marginal zone has been identified as early as nine weeks of gestation. In ventricle zone densely packed basophilic cells were seen. In intermediate zone, variable shape neuronal cells were seen. In hippocampal plate bipolar shape neurons were present. Marginal zone was predominantly populated by variable shaped cells.[8]

## 2. Aims and objective

In this study, an attempt was made to observe the morphological maturation and expressions of NCAMs in developing human hippocampus simultaneously. The findings of the present study were compared and discussed with the findings from the available literature.

## 3. Materials and methods

Aborted fetuses from 14 to 30 weeks of gestation were procured from the Department of Obstetrics and Gynecology, LN hospital after obtaining ethical clearance and written informed consent. Gestation ages were determined by measuring various parameters, such as Crown Rump Length, Biparietal Diameter and Foot Length. Brains were fixed in paraformaldehyde and slices of brain were dissected out from the prospective hippocampus. Slices of tissue were embedded in paraffin and 7 μm thick sections were cut using the rotary microtome. For each gestation age the tissue was stained with cresyl violet and H & E then observed for normal morphology. For each gestational age immune staining of the sections was done for the expression of NCAM. Stained tissue sections were observed with BX61 computerized Olympus microscope and images were captured with Olympus DP71 digital camera using Image Pro MC Software.

## 4. Observation and results (Table 1)

### 4.1. *14th Gestational weeks*

The primordial hippocampus was identified developing on the medial edge of inferior horn of lateral ventricle attaining its "C" shaped structure. Hippocampal fissure was formed and began to flex upon the parahippocampal gyrus. The subparts of hippocampus (Subicular complex, Ammon's horn and dentate gyrus) were identified following the curve of hippocampal fissure. At higher magnification the four fetal zones were clearly identified. Hippocampal plate was broad and more homogenous having darkly stained basophilic immature neuronal cells with thin cell processes in clusters. NCAM expression was seen in all the fetal zones. (Fig. 1a and b).

### 4.2. *18th Gestational weeks*

Hippocampus became more curved and mature, showing increase in its volume. Fimbriodentate and hippocampal fissure were seen. The Fetal zones were clearly identified. In hippocampal plate small, intense basophilic immature neuronal cells were seen with thin cells processes present in clusters. NCAM expression was seen in all the fetal zones, though staining intensity was more present in ventricular zone and hippocampal plate as compared to intermediate zone and marginal zone. The cell processes were also showing faint NCAM expression. In the dentate gyrus region granular cell layer was showing more of NCAM expression as compared to its molecular layer. (Fig. 2a and b).

**Table 1 – Observations.**

| Fetal zones | | 14 weeks | 18 weeks | 20 weeks | 22 weeks | 28 weeks |
|---|---|---|---|---|---|---|
| Ventricular Zone | Layers | 12–15 | 7–8 | 4–6 | 3–5 | 1–2 |
| | Density | ↑ | ↓ | ↓↓ | ↓↓↓ | ↓↓↓↓ |
| | Neurons | Neuroblasts | Immature neuronal cells | Mature neuronal cells | More differentiated neuronal cells | Well differentiated neuronal cells |
| Intermediate Zone | Neurons | Immature neurons | Immature neurons | Mature neuronal cells | More differentiated neuronal cells | Well differentiated neuronal cells |
| | Cell processes | ↓ | ↑ | ↑↑ | ↑↑↑ | ↑↑↑↑ |
| Hippocampal Plate | Neurons | Immature neurons | More differentiated neuronal cells | Few pyramidal cells | More differentiated pyramidal cells | Well differentiated pyramidal cells |
| Marginal Zone | Neurons | Immature neurons | Immature neurons | Mature neuronal cells | More differentiated neuronal cells | Well differentiated neuronal cells |
| | Cell processes | ↓ | ↑ | ↑↑ | ↑↑↑ | ↑↑↑↑ |
| NCAM expression | VZ | + | ++ | +++ | ++++ | +++++ |
| | HP | + | + | ++ | +++ | ++++ |

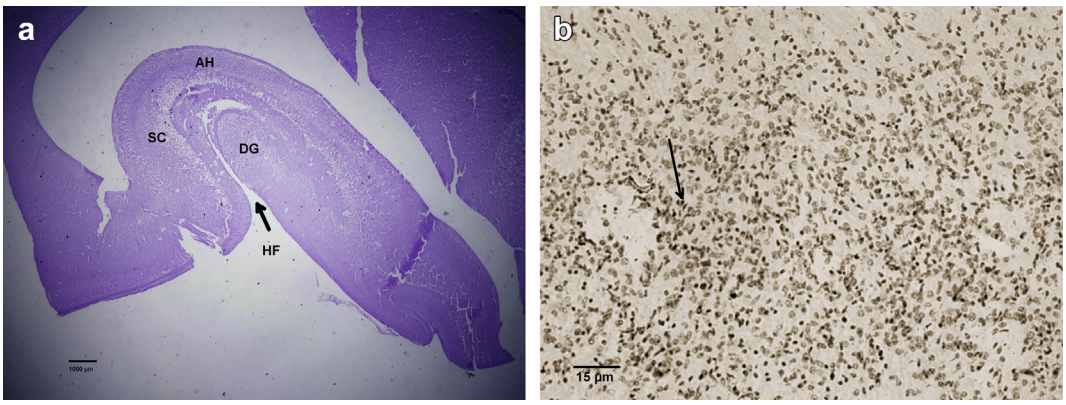


**Fig. 1 – a. Hippocampus of 14 week fetus showing dentate gyrus (DG), Ammon's horn (AH), subicular complex (SC) around the hippocampal fissure (HF) (arrow) developing inside the lateral ventricular cavity. b. Neuronal cells (arrow) showing intense NCAM expression along with cell processes having faint NCAM expression. (14 week fetus).**

### 4.3. *20th Gestational weeks*

The Pes hippocampi shape of hippocampus became more evident and volume of hippocampus had increased. Hippocampal fissure appeared to be longer and deeper. Subparts of hippocampus (Subicular complex, Ammon's horn and dentate gyrus) were clearly identified, following the curve of hippocampal fissure. Fimbria was seen extending just above the dentate gyrus. The morphology of dentate gyrus was more distinguished, characteristic granular cell layer was seen along with its molecular layer. In hippocampal plate small immature neuronal cells were present along with pyramidal

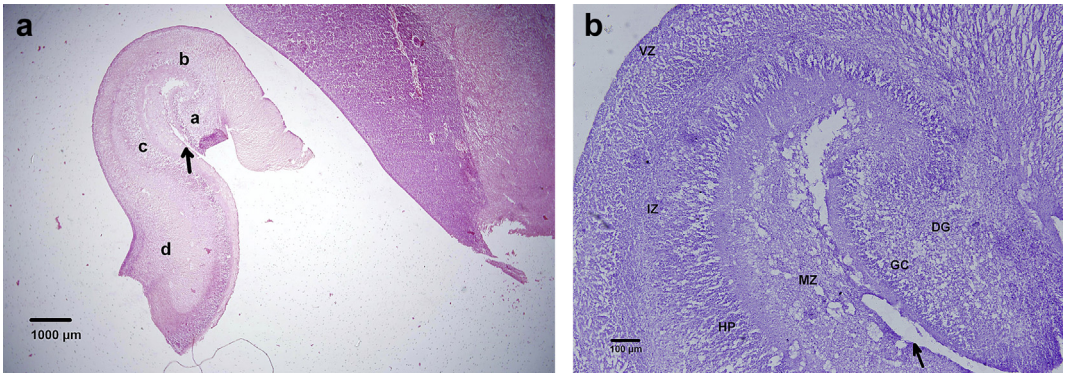


**Fig. 2 – a. Hippocampus of 18 weeks fetus showing dentate gyrus (a), Ammon's horn (b), subicular complex (c) and entorhinal cortex (d). Hippocampal fissure (arrow) seen. b. Ventricular zone (VZ), intermediate zone (IZ), hippocampal plate (HP), and marginal zone (MZ) seen along with granule cell layer (GC) of dentate gyrus (DG) around the hippocampal fissure (arrow). (18 week fetus).**

cells. Some transitional cells were also seen between neuroblast and pyramidal cells. NCAM expression was seen in all the fetal zones, though staining intensity was more present in ventricular zone and hippocampal plate as compared to intermediate zone and marginal zone. (Fig. 3a and b).

### 4.4. *22nd Gestational weeks*

Subparts of hippocampus (Subicular complex, Ammon's horn and dentate gyrus) were clearly identified following the curve of hippocampal fissure. Hippocampal plate was broad more homogenous in appearance, darkly stained neuronal cells were seen along with cell processes. Pyramidal cells were observed at this age along with small immature neurons. The morphology of dentate gyrus was more distinguished, characteristic granular cell layer was seen along with its molecular layer. NCAM expression was seen in all the fetal zones, though staining intensity was more present in ventricular zone and hippocampal plate as compared to intermediate zone and marginal zone.

### 4.5. *28th Gestational weeks*

Hippocampus attained almost mature appearance. Both fimbriodentate and hippocampal fissure were seen. Hippocampal fissure started fusing with the main body of hippocampus. Subparts of hippocampus, Subicular complex, Ammon's horn and dentate gyrus were clearly identified following the curve of hippocampal fissure. Fimbria was seen extending just above the dentate gyrus. Maturation of cells was in the more advanced stages. In hippocampal plate small immature neuronal cells were present along with pyramidal cells. Some transitional cells were also seen between neuroblast and pyramidal cells. Large and small pyramidal cells were present with various morphological differences. All the three layers of dentate gyrus were identified. Closely arranged, more mature spherical or oval granular cell neurons were present in granular cell layer giving axons into the polymorphous cell layer of dentate gyrus. NCAM expression was seen in all the fetal zones, though staining intensity was more present in ventricular zone and hippocampal plate as compared to intermediate zone and marginal zone. (Fig. 4a and b).

## 5. Discussion

The present study evaluated the histogenesis of hippocampus in the human fetuses ranging from gestational age 14 weeks–28 weeks. This is a morphological study where we have been able to observe the microscopic structure of entire hippocampal formation including dentate gyrus and correlated this with the expression of NCAM. The development of nervous system is a very intricate process, starting from the formation of neural plate to the fully mature brain. All cells of the nervous system are derived from neuroepithelial cells lining the neural tube. In the process of development of nervous system, the order of maturation of different functional areas is different. The difference in the maturation levels also differ in different species, even in the same functional area.[9] The morphological maturation of hippocampus correlates well with functional maturation. The plasticity of a specific hippocampal synapse has a significant role in memory formation and hippocampal dependent task. Dentate granule cells have the unusual property of prolonged postnatal neurogenesis and thus play an important role in pathogenesis of temporal lobe epilepsy.[10] Hippocampal neuroepithelium consists of three morphologically discrete components-the Ammonic neuroepithelium, the primary dentate neuroepithelium, and the fimbrial glioepithelium and these are discrete sources of large neurons of Ammon's horn, the smaller granular neurons of the dentate gyrus, and the glial cells of the fimbria.[5] In the present study the lowest age of fetus included is 14 weeks where the primordial hippocampus was identified developing on the medial edge of inferior horn of lateral ventricle. Subparts of hippocampus were identified along the curve of hippocampal fissure. In the early development of hippocampus four fundamental embryonic zones has been delineated. These zones are ventricle zone, intermediate zone, hippocampal plate and marginal zone. Each of these zones either disappears or is untraceable in the mature hippocampus which has also been identified by

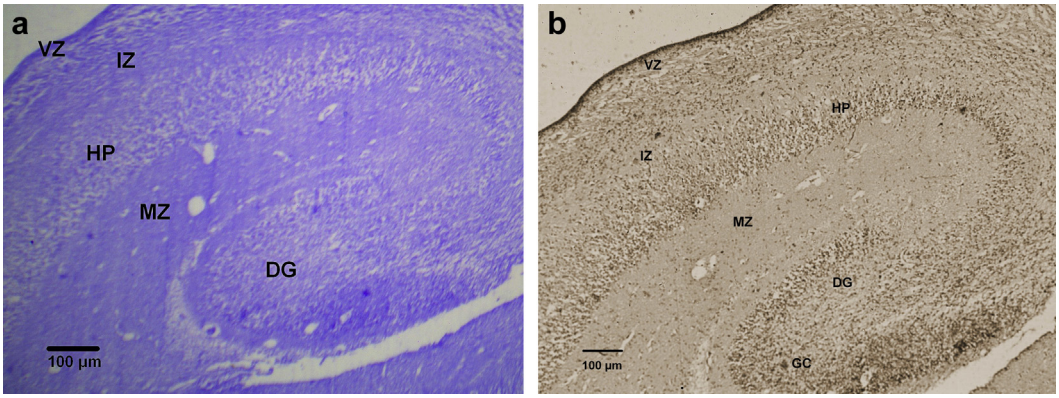


**Fig. 3 – a. Ventricular zone (VZ), intermediate zone (IZ), hippocampal plate (HP), and marginal zone (MZ) seen along with granule cell layer of dentate gyrus (DG) at higher magnification. (20 week fetus). b. NCAM expression seen in ventricular zone (VZ), intermediate zone (IZ), hippocampal plate (HP), and marginal zone (MZ) along with granule cell layer of dentate gyrus (DG). (20 week fetus).**

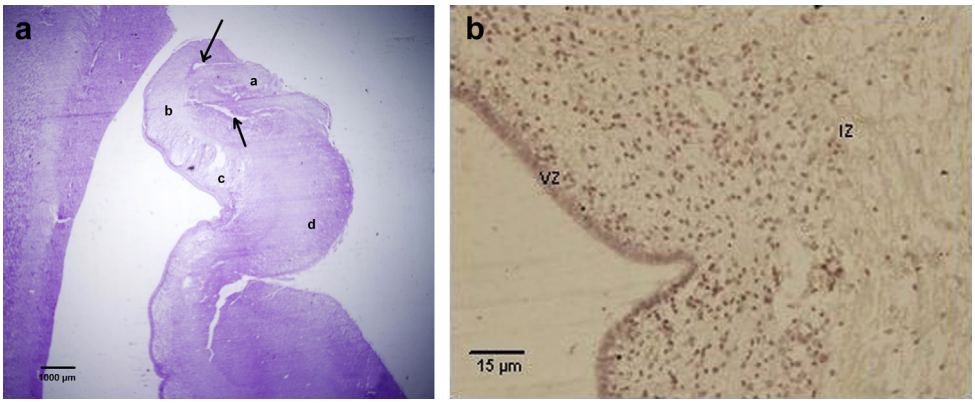


**Fig. 4 – a. Hippocampus of 28 weeks fetus showing dentate gyrus (a), Ammon's horn (b), subicular complex (c) and entorhinal cortex (d). Fimbriodentate and hippocampal fissure (arrow) seen fusing with the main body of the hippocampus. (28 week fetus). b. Neuronal cells showing NCAM expression in ventricular zone (VZ) and intermediate zone (IZ) along with neuronal cell processes at higher magnification. (28 week fetus).**

previous workers.[8,11,12] In our study also these four zones visualized in all the fetuses studied. Ventricle zone was seen as darkly stained layer having immature basophilic neuronal cells as compared to lighter stained intermediate zone. A broad homogenous hippocampal plate was seen having immature neuronal cells along with cell processes. Our findings corroborates with other studies done on the development of human hippocampus.[8,11,12]

At 14 weeks of gestation we could appreciate the NCAM expression in all the fetal zones. NCAM expression was seen more strong in ventricle zone and granule cell layer of dentate gyrus. The fascicles were also showing faint NCAM expression. This pattern of NCAM immune reactivity suggests that differentiation and migration is occurring at 14 weeks. This study is with concurrence with previous work done on human fetuses.[13,14] In present study at 18 week of gestation, gradual maturation of cells was seen. Hippocampus became more curved having its mature appearance. Sub parts of hippocampus were clearly identified. Ventricle zone thinning had occurred. In previous study done on human fetuses well distinguishable pyramidal cells were present at 15th week of gestation.[8] However in present study we had not seen pyramidal cells even at 18th week of gestation. There was increase in the intensity of NCAM expression in 18 week fetus as compared to 14 week fetus. At 20 week of gestation cells became more distinct as compared to 18 week fetus. Pyramidal cell morphology became more evident in hippocampal plate as compared to early week fetus. NCAM expression was similar to earlier 18 week fetus. This observation was in concurrence with another studies done on human fetuses.[8,11,12]

At 22 weeks of gestation there was gradual increase in the maturation of cells. Pyramidal cells present in hippocampal plate were showing more differentiation. There was increase in the expression of NCAM as compared to early week fetuses however pattern of NCAM expression remained same. The presence of NCAM in embryonic life and adult brain is highly correlated with neuronal precursor migration and differentiation.[13–15] Earlier work on human hippocampal formation had shown that cytoarchitectonic layers of Ammon's horn were formed before 24th gestational week. Pyramidal neurons present in the hippocampal plate were generated in the first half of pregnancy and no pyramidal neurons were formed after 24th week of gestation.[12] It is in concurrence with present study, where pyramidal cells were seen at 20th week of gestation.

At 28 weeks of gestation hippocampus attained almost mature appearance. Fimbriodentate and hippocampal fissure was seen fusing with the main body of hippocampus. In dentate gyrus region granule cell layer became more evident relative to the earlier 22nd weeks fetus. NCAM expression was seen in all the fetal zones having similar pattern as seen in earlier week fetus.

Thus from the present study it is evident that the hippocampus attains almost complete maturation by 28 weeks of gestation. To observe complete maturation higher gestational ages are required. Although the essential cytoarchitectonic of hippocampal subfields is stable after birth, there is progressive neuronal enlargement and increase in neuronal density from childhood to adulthood.[16]

## 6. Conclusion

Hence by our study we conclude that as the age advances ventricular zone thinning occurs, cells become more differentiated and enlarged. More intense NCAM expression in ventricle zone and granule cell layer of dentate gyrus indicates more cell differentiation and migration in those layers.

## Conflicts of interest

All authors have none to declare.

## REFERENCES

1. Standring S. *Gray's Anatomy*. 39th ed. Elsevier Churchill Livingstone; 2005:p387–417.

2. Miller DB, O'Callaghan JP. Ageing, stress and the hippocampus. *Ageing Res Rev*. 2005 May;4:123–140.
3. Snell RS. *Clinical neuroanatomy*. 6th ed. Lippincott Williams & Wilkins; The Reticular Formation and the Limbic System; 2006:298–305.
4. Angevine JB. Development of the hippocampal formation. In: *The Hippocampus*. New York: Plenum Press; 1975:61–90.
5. Altman J, Bayer SA. Mosaic organization of the hippocampal neuroepithelium and the multiple germinal sources of dentate granule cells. *J Comp Neurol*. 1990;301:325–342.
6. Kuhn HG, Anson HD, Gage FH. Neurogenesis in dentate gyrus of the adult rat: age related decrease of neuronal regenerator proliferation. *J Neurosci*. 1996 March 15;16:2027–2033.
7. Seri B, Garcıa-Verdugo JM, McEwen BS, Alvarez-Buylla A. Astrocytes give rise to new neurons in the adult mammalian hippocampus. *J Neurosci*. 2001;21:7153–7160.
8. Arnold SE, Trojanowski JQ. Human fetal hippocampus development cytoarchitecture, myeloarchicture, and neuronal morphological futures. *J Comp Neurol*. 1996;367:274–292.
9. Rakic P, Nowakowski RS. The time of origin of neurons in the hippocampal region of the rhesus monkey. *J Comp Neurol*. 1981;196:99–128.
10. Bischofberger J, Schinder AF. *Adult neurogenesis*In: *Maturation and Functional Integration of New Granule Cells into the Adult Hippocampus*. vol. 52. 2008:299–319.
11. Kostović I, Seress L, Mrzljak L, Judas M. Early onset of synapse formation in the human hippocampus: a correlation with Nissl-Golgi architectonics in 15-16.5-week-old fetuses. *Neuroscience*. 1989;30:105–116.
12. Seress L, Abraham H, Tornoczky T, Kosztolanyi G. Cell formation in the human hippocampal formation from mid gestation to the late postnatal period. *Neuroscience*. 2001;105:831–843.
13. Huttenlocher PR, Dabholkar AS. Regional differences in synaptogenesis in human cerebral cortex. *J Comp Neurol*. 1997;387:167–178.
14. Bukalo O, Fentrop N, Lee AY, Salmen B, Law JW. Conditional ablation of the neural cell adhesion molecule reduces precision of spatial learning, long-term potentiation and depression in the CA1 subfield of mouse hippocampus. *J Neurosci*. 2004;24:1565–1577.
15. Theodosis DT, Bonhomme R, Vitiello S, Rougon G, Poulain DA. Cell surface expression of polysialic acid on NCAM is a prerequisite for activity-dependent morphological neuronal and glial plasticity. *J Neurosci*. 1999;19:1028–1036.
16. Seress L. Neuronal connections, cell formation and cell migration in the perinatal human hippocampal dentate gyrus. *Cesk Fysiol*. 1998;47:42–50.