Available online at www.sciencedirect.com

ScienceDirect

journal homepage: www.elsevier.com/locate/jasi

Original Article

Mapping the time line of senescent changes in human retinal histology from third to tenth decade

*Tulika Gupta**, *Daisy Sahni*

Department of Anatomy, Postgraduate Institute of Medical Education & Research, Sector-12, Chandigarh 160012, India

ARTICLE INFO

Article history:
Received 20 March 2015
Accepted 1 April 2015
Available online 20 April 2015

Key words:
Ganglion cells
Retinal histology
Retinal senescence
Nerve fibre layer
Photoreceptors

ABSTRACT

Introduction: Retinal pathologies causing irreversible visual loss are very common in India especially in advance age. Increased understanding of the age related structural and functional changes in retina can immensely help in better diagnostic and therapeutic modalities.

Methods: Twenty five human retinal tissues from 21 years to 99 years of age were studied histologically and changes seen with H&E staining, in each retinal layer, are described. Special stains and specific immune labelled antibodies were used to understand the changes better.

Results: Retinal pigment epithelium showed, gradual reduction in cell size, melanin granules and increase in lipofuscin content & increase in bruch's membrane hyalinization with age. As age advanced there was reduction in the ratio of the rods and cones, thickness of the outer plexiform layer, ganglion cell count and thickness of the nerve fibre layer. The thicknesses of all the retinal layers and the ganglion cell count have been documented decade wise.

Conclusions: This detailed description may aid in improved management of diseases that are characterized by abnormal or premature aging as well as in understanding the age related retinal disorders. This data will also improve the interpretations of images of retinal micro anatomy obtained in patients by spectral domain-optical coherence tomography (SD-OCT), routinely used by ophthalmologists.

1. Introduction

Most of the retinal diseases lead to either irreversible blindness or severe visual loss and therefore are a cause of immense morbidity. Incidence of retinal pathologies increases with advancing age and results in severe limitation in productivity and reduction in the quality of life. Newer diagnostic and treatment modalities are emerging; most of them at best arrest the progress of retinal disorder or slow it. To develop curative treatments it is imperative to have a

* *Corresponding author*. Tel.: +91 9815610227.
E-mail address: tulikag11@yahoo.com (T. Gupta).
http://dx.doi.org/10.1016/j.jasi.2015.04.004

detailed knowledge of morphology and functioning of various elements which constitute the retina. Full comprehension of chronology of age related changes in various layers of retina is essential as many senescent modifications predispose the tissue to pathogenesis. This knowledge would help to unravel the different steps involved in the development of age related retinal diseases.

Decades of research has led to a better understanding of numerous anatomic modifications seen in the retina with age. These changes progress slowly and vary in severity in different individuals. These changes are also found in age-related macular degeneration (AMD), a late onset disease that severely impacts the vision, but the changes are much more pronounced than during normal aging. Most of the available studies on age related changes have been done either on animal models[1–5] or clinically by optical coherence tomography[6,7] with limited literature on human tissue.[8–12]

Spectral domain optical coherence tomography (SD-OCT) has renewed the interest in the base line data on non-pathological age related changes for ready reference. A comprehensive data, on senescent alterations in retinal histology in successive decades of life, is not available in literature. Details and timeline of age related changes in retina can provide significant insights, which may aid in formulation of early and better diagnostic criterion and may prove helpful in development of curative treatment modules. Therefore the present study was planned to record various histological senescent changes from 2nd to 10th decade of life.

2. Materials and methods

This is a cross-sectional histological study on retina from 25 pairs of adult eyeballs. All the specimens were studied after H & E staining. The PAS (Periodic acid schiff) staining was done on selected tissues. In addition all the specimens were subjected to immune histochemical staining, using three primary antibodies for better characterization.

2.1. *Material*

Adult eyes balls from unembalmed cadavers (received through body donation programme running in the department of Anatomy PGIMER, Chandigarh) and from eye donation programme, were used for the study. Twenty five fresh adult eyes, ranging from 21 years to 99 years of age were studied Specimens with history of ocular disease, ocular trauma, hypertension or diabetes were excluded from the study. Ethical clearance was taken from the institutional ethical committee.

2.2. *Methods (Fig. 1)*

Eye balls from the cadavers were enucleated with the help of an enucleation spoon. Each eye ball was sectioned parallel to the equator nearer to the posterior pole and fixed in 10% buffered formalin. This was followed by paraffin embedding,

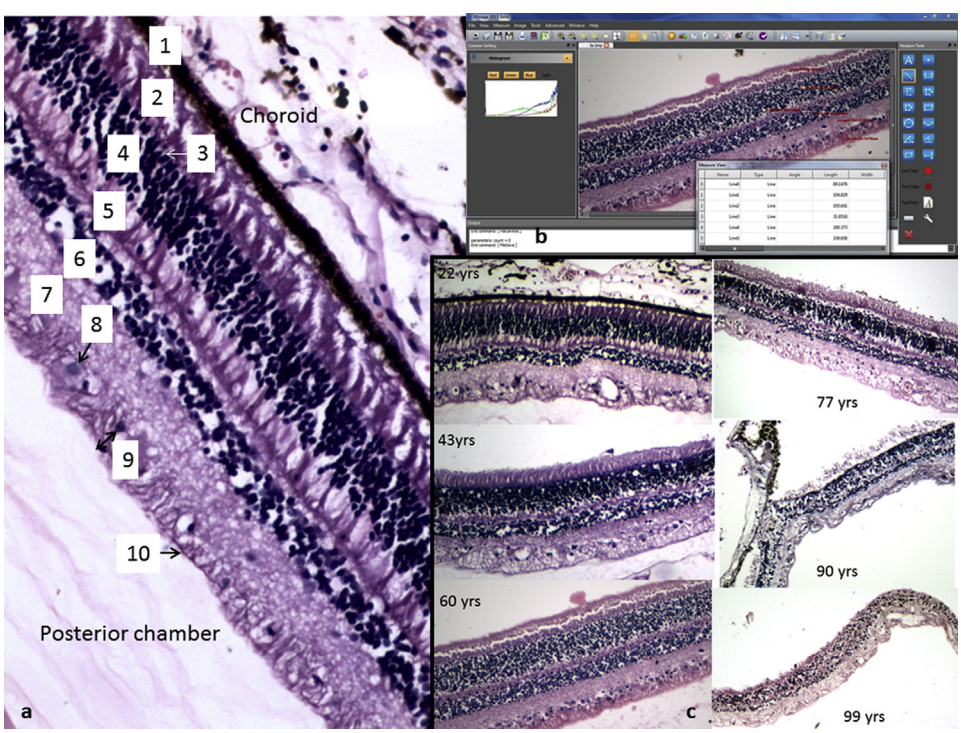

Fig. 1 – a. H & E stained section of retina seen at 20× magnification. Choroid is seen on the right side with retinal pigment epithelium (RPE) forming dark line at the outermost aspect of retina. The successive inner retinal layers are seen on the left of the RPE. 1. RPE 2. Photoreceptor layer 3. Outer limiting membrane 4. Outer nuclear layer 5. Outer plexiform layer 6. Inner nuclear layer 7. Inner plexiform layer 8. Ganglion cell layer 9. Nerve fibre layer 10. Inner limiting membrane b. Photograph depicting the method used for the morphometry of various retinal layers with the help of V-Test software, 198035. c. The generalised attenuation of total retinal width with age is depicted. (10×).

block making and sectioning. The sections for haematoxylin and eosin staining (H&E) were 5 micron thick while for the immuno-histochemistry (IHC) 4 micron thick sections were taken on the Poly L-lysine coated slides. The H&E and PAS staining were done by regular protocol. For the IHC Avidin–Biotin–peroxidase complex (ABC) technique[13] was followed: The paraffin sections were deparaffinised, then hydrated gradually and washed in de-ionised water. Endogenous blocking, to quench the activity of endogenous peroxidase was done. It was followed by antigen retrieval. The slides were then incubated with primary antibodies followed by secondary antibody. The sections were treated with DAB (3,3′-diaminobenzidine) and counter stained with haematoxylin. Following primary antibodies (Dako, Denmark) were used:

- Anti neuro filament protein (NFP) antibody (Monoclonal Mo a Hu Neurofilament Protein)
- Anti synaptophysin antibodies (Monoclonal Mo A Hu Synaptophysin)
- Anti S-100 antibodies (Polyclonal Rb a S100)

Anti NFPand anti synaptophysin were human monoclonal antibodies while anti S-100 was polyclonal. **Positive control** of colon tissue was used for all the antibodies while **negative control** was obtained by omitting the primary antibody.

Morphometry (Fig. 1c): Each specimen was studied and micro photograph was taken with the help of Ci-L Pentahead Nikon microscope (700857) with camera (MC 30). The photographs were transferred to the computer. The measurements of various retinal layers were taken on photographs taken at 100× magnification with the help of V-Test software, 198035 (Russia, St.-Petersburg, 2009). The cell count for the rods and cones cells and ganglion cells was done in ten high power fields (400× magnification) and mean value was taken.

3. Results

We describe the histological features of each layer of retina and changes as observed with increase in the age from 21 years to 99 years. The most evident feature observed was generalized attenuation of all retinal layers with gradual thinning of retina with age (Fig. 1c). The human retina is arranged in ten distinct layers (from outside inwards) (Fig. 1a):

1. **Retinal pigment epithelium (RPE)** (Fig. 2): At the age of 21 and 22 years the RPE was seen as single cell thick layer of cuboidal cells. The haematoxylin stained nucleus of each cell was rounded, vesicular, basally placed and mostly covered by melanin granules. The granules were multiple, discrete, brown staining and present in all parts of cell but concentrated more on the apical (inner or retinal) side of the cell. The RPE cells rest on the basement membrane which fuses with the basement

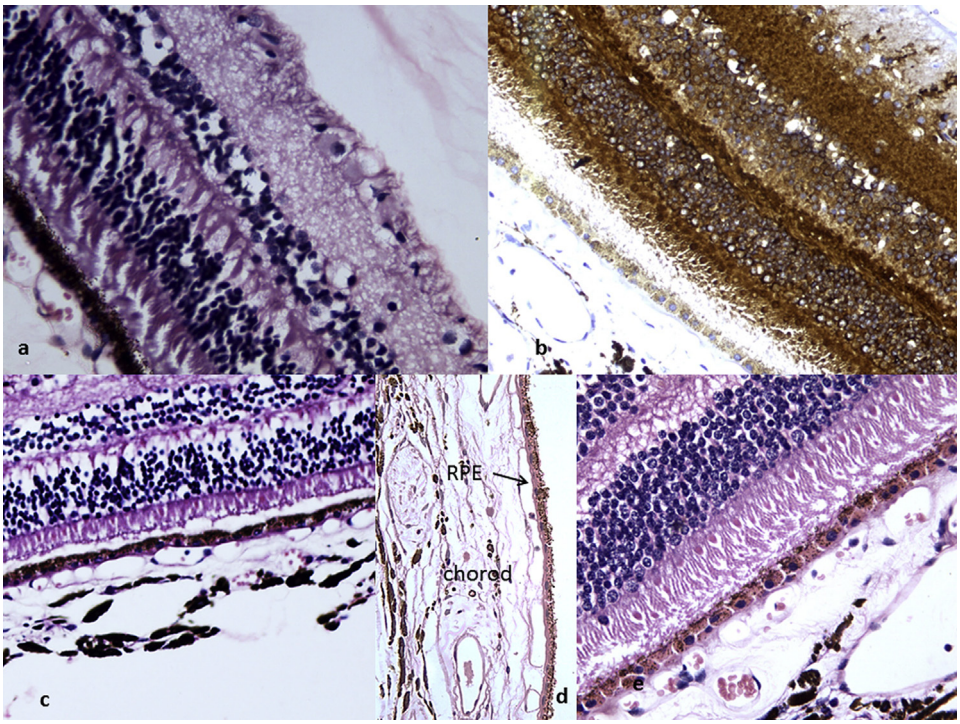

Fig. 2 – a. Twenty two year old retina stained with H&E (20×). The RPE cells are fully filled with melanin granules which also covers most of the basally located nucleus. Thin bruch's membrane is seen b. 43 years old retina immunostained with synaptophysin (SP) antibodies (40×) showing thickening of the bruch's membrane. Fewer granules are seen and nucleus is exposed. c. d. Shows 67 and 84 yrs old retina respectively. RPE cells are attenuated with reduced pigmentation and thickened bruch's membrane. e. H& E stained (40×) specimen of 60 yrs old retina. The macular region is shown as evident by multilayered ganglion cells. The RPE is stratified; 2–3 cell thick layer, with polyhedral cells. One binucleate RPE cell can be seen.

membrane of the choroidal capillaries. The fused membrane, known as Bruch's membrane was seen as a thin but distinct membrane. From the apical aspect of the RPE cells thin eosinophilic extensions were seen going into the layer of rods and cones. These extensions were devoid of granules. We found gradual senescent reduction in these apical microvilli.

At 43 years of age the RPE cells were plump cuboidal as before but basal nucleus with dispersed chromatin was clearly seen in each, as it was not covered by the granules. The granules were present in the retinal or apical half of the cell extending either up till the nucleus or covering small apical part of the nucleus. Only in few cells the granules were present throughout the cell, covering the nucleus fully and reaching up to the basal part of the cells. In the early sixties (60 year, 60 year and 62 year) the RPE cells were attenuated. There was small decrease in the height of the cell with smaller; less intensely stained nucleus. The intra cellular granules were reduced. There were 4–5 interspersed areas where retinal pigment epithelium is stratified, 2–3 to 5–6 cells thick. In such areas of RPE proliferation the cells are polyhedral with central round nucleus and are filled with granules. One such area was seen at the macula but rest were present in the peripheral retina.

In the latter half of 6th decade (2 cases of 67 years) segments showing RPE proliferation were predominant. In most of the areas the RPE was two cells thick but in macular area it was 5–6 cells thick. The bruch's membrane was thickened. In the early seventies (70 years, 71 years and 73 years) the hyalinization of the bruch's membrane was more advanced. In one case apart from few areas of simple epithelium the whole expanse of the RPE was found to be two cells thick. In the areas with single cell thickness many cells appeared binucleate. The macular RPE was 2 cells thick. In another case the whole RPE was found to be attenuated throughout its expanse with reduced cell size and fewer granules. None of the areas had any sign of RPE proliferation.

In late 70s (77 years two cases, 78 years 2 cases and 80 years) the RPE cell size seemed to decrease further with almost squamous like cells and sparse granules with thicker bruch's membrane.

During 9th decade (82 years, 83 years, two cases of 84 years, 85 years and90 years) and 10th decade (91 years, 95 years and 99 years) progressive RPE attenuation was found. In 90s the granules were severely depleted. The bruch's membrane was thick

2. **Layer of rods and cones** (Fig. 3): This layer has two parts, the outer segment (towards the RPE) and the inner segment.

In the third decade this photoreceptor layer was seen as the thick layer with the width of 110.94 μ. The ratio of number of rods and cones in the peripheral retina was observed to be 25:1 to 30:1. PAS stain selectively labelled the outer part of the layer (Fig. 4 last panel). In the immune labelled slides the anti synaptophysin antibodies (anti SP) localized to the inner segments of the photoreceptor while the outer segments takes the base stain only (Fig. 3 1st panel). With the anti neurofilament antibodies (anti NFP)

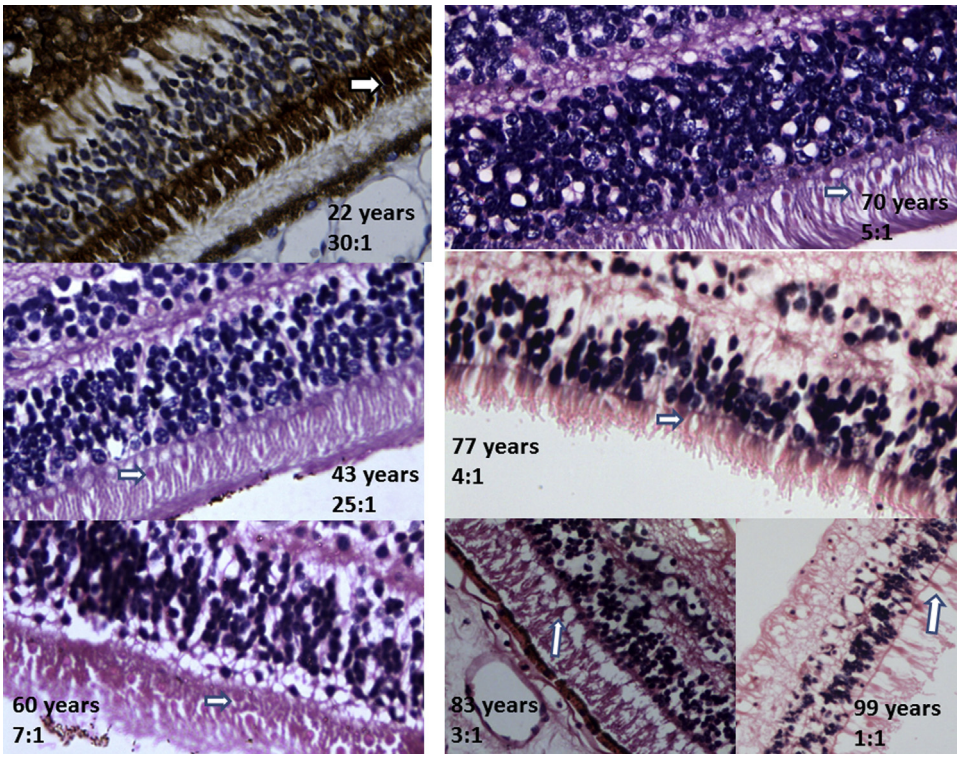

Fig. 3 – The gradual reduction of rods photoreceptors (white arrow) with falling rods: cones ratio seen with increasing age. Solid arrow is showing inner limiting membrane (40× H & E except first panel which is immunostained with anti synaptophysin antibodies).

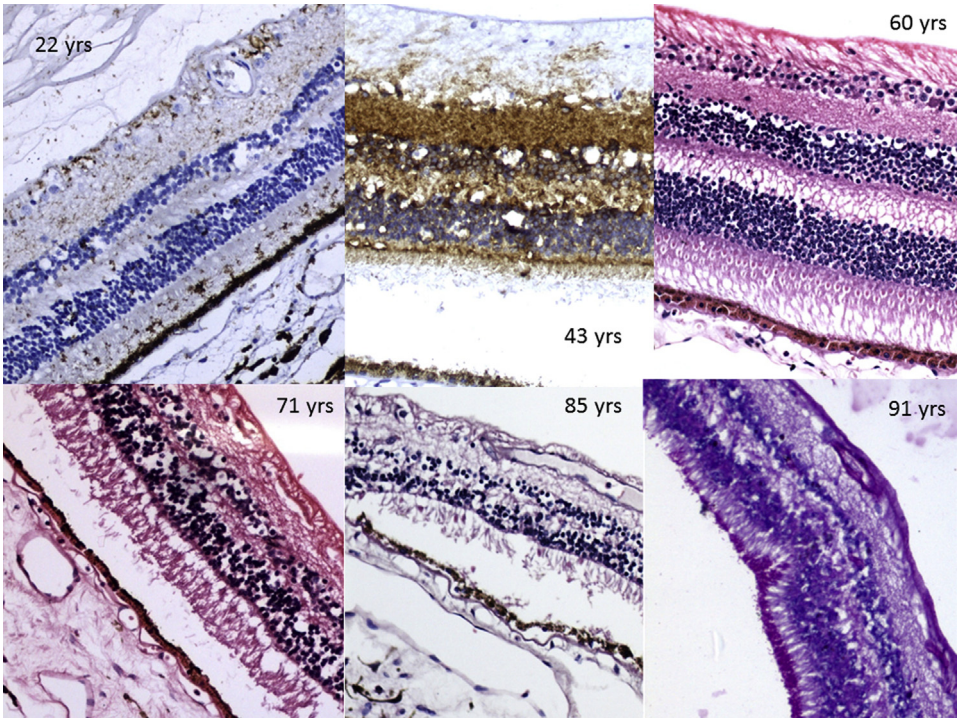

Fig. 4 – Twenty two to 91years old retinal specimens depicting age related changes in the outer nuclear layer (ONL), outer plexiform layer (OPL), inner nuclear layer (INL) and inner plexiform layer (IPL) are shown. Age related thinning of all the layers but especially OPL is evident (20×). Increased vascularity of retina in specimens from late 8th to 10th decade was observed. 1st panel is stained by anti neurofilamentry protein antibodies, second panel is stained with anti S-100 antibodies and the last panel is stained by the PAS stain. Rest of the panels are H&E stained.

localization was spotty and irregular marking of the most outer (towards RPE) parts of the layer was seen (Fig. 4 1st panel).

In the early sixties this layer appears much thicker as compared to other layers of retina as it maintains its thickness while other layers seem to shrink, though in later years the thickness of photoreceptor layer also decreases. The most remarkable change was found in the ratio of rods: cones which reduced to 7:1 in early 60s. In late 60s it was found to be 5:1 with progressive and consistent decline to 4:1 to 3:1 in the 8th decade and 3:1 in the 9th decade. In the specimens of 10th decade the rods were degraded so much and the ratio of rods: cones were found to be 1:1 in 99 years old.

3. **Outer limiting membrane (OLM)** (Fig. 3): This was seen as an eosinophilic thin membrane. The integrity of this membrane was maintained with aging. Even in specimens from late 90s the layer was intact, clearly demarcated though slightly thicker. This membrane is delineated best by H&E and anti synaptophysin antibody labelling.
4. **Outer nuclear layer (ONL)** (Figs. 3, 4): It is seen as thickest layer 6–8 cell thick measuring 103.82 μm to 160.37 μm from 3rd to the 5th decade. Later on as with other layers the thickness start to decrease with 138.74 μm in 7th, 63.7 μm in the 8th, 60.09 μm in the 9th and 58.37 μm in the 10th decade. Uniform densely staining oval nuclei, with no nucleoli, of photoreceptor cells constitute this layer in specimens from the 3rd and 5th decades. In the specimens of retina from 6th decade the nuclei showed reticular sparse staining pattern but in still older retinas of the staining was even (non reticular) though less intense. Vessels were not seen in this layer.

Anti SP localization was found in between the nuclei but staining was more intense in inner 1/2 to 1/3 of the layer (Fig. 3). The staining became sparse with increasing age as seen from seventies and onwards. From 8th decade this layer seemed to mix with the inner nuclear layer at places with almost complete merging observed in some specimens of early 80s. But this was not seen in all the specimens from late eighties and nineties. Even in the retina of 10th decade both the inner and outer nuclear layers are seen as distinct layers with very thin outer plexiform layer separating them (Fig. 4).

5. **Outer plexiform layer (OPL)** (Figs. 3, 4): This layer is seen as the thinnest layer apart from the limiting membranes and the RPE. In the centre of this layer middle limiting membrane was clearly seen. Vessels were not found in the OPL in any of the specimens. This layer was about 46–47 μm thick in 3rd and 4th decade, 36 μm in early 60s, 24 μm in late 60s. This declining trend in thickness was maintained, in 8th and 9th decade and it was found to be 09–20 μm thick. In some specimens from 7th to 9th decade complete obliteration of this layer was seen at few places. Such areas increased in size with age. The middle limiting membrane was not evident in the specimens of 70 years and beyond.

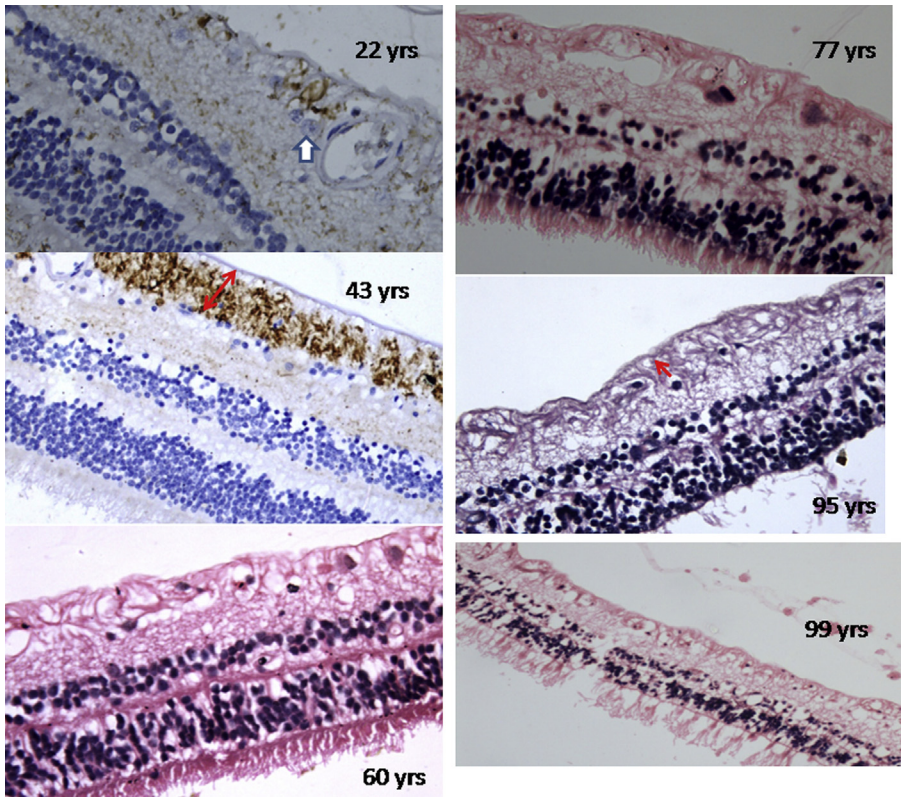

Fig. 5 – Ganglion cells density (white arrow) and nerve fibre layer thickness (red arrow) decreases with advancing age. First two panels have tissue immunostained with anti neurofilamentry protein while the rest are H&E stained.

The anti SP stains the layer but the localization is more intense in the inner 2/3 of the layer.

The anti S-100 gives faint staining with clear demarcation of the middle limiting membrane.

6. **Inner nuclear layer (INL)** (Fig. 4): This layer is 5–6 cells thick. Different types of nuclei were noted in this layer. Predominant type was round nucleus having lattice like DNA arrangement with no nucleoli. These were smaller in size as compared to the ganglion cell nuclei. Second type of nucleus was oval or fusiform with intense and even staining. In the slides labelled with anti SP antibodies dense synaptic connections which almost enclose the cells all around, were evident (Fig. 2 2nd panel). The gradual thinning of the layer with age was noted. Retina of the 8th decade showed 3-4 small capillaries in the peripheral parts of the inner nuclear layer. At macula multiple capillaries were seen.
7. **Inner plexiform layer (IPL)** (Fig. 4): This layer also showed gradual attenuation in width from 94 μm in the 3rd decade to 46.9 μm in the 9th decade. At regular intervals capillaries were seen. Some capillaries were small in size and were confined to this layer but there were many large capillaries which spanned nerve fibre layer, ganglion cell layer and inner plexiform layer. Almost all the capillaries occupied the inner 2/3 of the layer. Ganglion cell (GC) dropout into the IPL was not seen in the 3rd decade, occasional GC dropout was noted in the 43 years and early 6th decade retinal specimens. After that age GC dropout was seen as a regular feature with 2–4 ganglion cell noted in every high power field (400×). In the specimens from late 7th decade onwards the fibre network seems sparse with marginally less intense staining by anti SP, which stained the IPL most among all the layers (Fig. 2 2nd panel).
8. **Ganglion cell layer (GCL)** (Fig. 5): This was seen as single cell layer in the periphery but in macular region it became stratified to 5–6 cell thickness. The nuclei were large (biggest in retina), vesicular with dispersed chromatin and distinct nucleoli. Among these few scattered small dense staining nuclei were also noted. These can either belong to the retinal glial cells or can be of ganglion cells but seen in profile.

Ganglion cell count of peripheral retina demonstrated consistent and significant decrease with age. It was 33–48/HPF until late 5th decade which dropped to 20/HPF in early 70s, 12/HPF in early 80s to 10/HPF at mid-90s and 9/HPF at 99 years of age. The ganglion cell layer had capillaries, number of which increased with age from 2 to 3 in the whole expansion 3rd and 5th decade to 2–4 capillaries per high power field (400×) in later years.

Anti SP localization was seen in the outer half of the ganglion cells, delineating synapses which are between the axons from the inner nuclear layer cells and ganglion cells. Anti SP antibodies did not localise in the inner aspect of the ganglion cell as axons emerging from here form the nerve fibre layer but do not participate in any synapse formation.

Anti S-100 delineated fibre network around the ganglion cells (Fig. 2 2nd panel, Fig. 5).

9. **Nerve Fibre layer (NFL)** (Fig. 5): This layer was seen as a thick fibrous layers with fibres running at right angles to the retinal surface. Capillaries were noted as described above in the IPL and ganglion cell layer. Anti NFP antibodies delineated this layer the best, as they localised only in nerve fibre layer. Anti S-100 also localised to the NFL. This layer showed marked reduction in thickness with age from 77.19 μm at 3rd decade, 69.15 μm in 4th decade, 73.02 μm in 7th decade, 53.92 μm in the 8th decade, 35.96 μm in the 9th decade to 26.64 μm in the10th decade. Staining with NFP became patchy and less intense with age. The nerve fibre layer reduction was more remarkable at macula as compared to the peripheral retina.
10. **Inner limiting membrane (ILM)** (Fig. 5): It was seen as a distinct eosinophilic membrane. It did not stain with anti SP, anti NFP or anti S-100 antibodies. In some specimens of 7th decade ILM was thickened and more eosinophilic. The integrity of the internal limiting membrane was found to be maintained even in 99 year old retina. Preretinal eosinophilic thin membranes were noted inner to the ILM, in the few specimens belonging to the 9th and 10th decades.

4. Discussion

The ability to identify and quantify disease state and related pathophysiology depends on clear understanding of normal histology and age related alterations seen in various constituents of retina. Here we have described distinctive changes seen in aging retina. Most consistent and striking change is in overall thickness of retina which shows gradual reduction, contributed by all the layers.

Retinal pigment epithelium serves many phagocytic, metabolic synthetic and supportive functions It is an important component of blood retinal barrier.[14] With aging, the RPE becomes more pleomorphic, with the macular RPE becoming narrower with an increased height, and opposite occurring in the periphery. The peripheral RPE cells become broader, lower, vacuolated and pleomorphic with aging.[15,16] In our study attenuation of the RPE was evident at 60 years of age with cells reduced to squamous shape in late 70s. Narrowing of RPE was found in peripheral as well as macular retina. In some specimens belonging to the 7th decade large polyhedral RPE cells arranged in layers were present but such areas were seen at macula and periphery both. The gradual loss of melanin pigment has been reported.[17,18] We also found gradual age related depletion of melanin granules. This depletion became very striking in the 9th decade. In the areas showing RPE proliferation, the polyhedral cells were found filled with the melanin granules.

Most striking observation in the photoreceptor layer was found to be age related decline in number of rods in the peripheral retina from 6th decade onwards. In the 99 year old retinal specimen the rods and cones ratio was found to be 1:1 as against the 30:1 ratio in the 2nd decade. During normal ageing, the rods (and other neurons) undergo a significant decrease in density in the human retina from the fourth decade of life onward.[19] Curcio et al. (1993)[20] have demonstrated a progressive, age-related loss of rods before cones in the macula with an accompanying decline in scotopic sensitivity compared to photopic sensitivity. Outer and inner nuclear layers tend to merge in advanced age with obliteration of the outer plexiform layer, though we found that it is not an invariable feature. Retinal degeneration characterized by atrophy of photoreceptors and partial degeneration of neurons in the outer nuclear layer has been reported in the rat retina. These changes are attributed to low-intensity light damage related to aging. Loss of inner retinal layers was observed only after complete loss of photoreceptor cells.[3] In the aged retina, an overall thinning is apparent, due to loss of neurons from all the neuronal cells and also shortening of photoreceptor cells. The elderly suffer from loss of visual acuity, colour perception and dark-adaptation sensitivity. These conditions are probably associated with age-related death of RPE and photoreceptors.[18,21]

Progressive retinal nerve fibre layer (RNFL) thinning is associated with aging. Glaucoma is also associated with progressive RNFL thinning and RNFL thickness variation over time is used for the evaluation of glaucoma. Considering both age and glaucoma cause progressive RNFL thinning, it is important to assess the rate of RNFL thinning associated with age for the accurate evaluation of glaucoma. It was found to decrease from 99.04 ± 4.20 μm in 20–29 year age group to 89.60 ± 4.73 μm in 60–79 year age group.[22] Overall mean RNFL thickness decreased by 0.365 μm for every one year increase in age.[23] Given the importance of RNFL thickness as a means for quantifying glaucomatous damage histologically, the paucity of high-quality data on retinal nerve fibre thickness is a drawback. We noticed marked reduction in RNFL thickness with age from 77.19 μm at early twenties to 26.6 μm at 99 years. Age wise data has been compiled in our study. Fibres were found to be running at right angles to the retinal surface not parallel to it as has been described.

Another method to quantify glaucomatous damage histologically is to use ganglion cell body count. Though death of ganglion cells is the common final pathway event in glaucoma pathophysiology, it is also observed in normal aging. Ganglion cell dropout can therefore provide an accurate assessment of the damage inflicted by the disease process if age related data is available. This histological approach, while potentially powerful, is extremely labour intensive.[24] In the present study marked age related ganglion cell count drop was found from 48/HPF at 22 years to 9/HPF at 99 years of age. We have documented GC count for each decade.

Conclusion: In order to achieve a better understanding of disease processes affecting the retina, this study describes age related changes as seen in each layer. It is important to be aware of the range of senescent attenuation so as to differentiate them from pathological processes involving retina. Moreover as newer OCT technologies have enabled clinicians to recognize and quantify disease states by visualising cross sectional retinal anatomy, we have attempted to provide a comprehensive histological description of retinal layers across different age groups which can be used as baseline data for ready reference by clinicians and pathologist.

Conflicts of interest

All authors have none to declare.

REFERENCES

1. Chidlow G, Daymon M, Wood JP, Casson RJ. Localization of a wide-ranging panel of antigens in the rat retina by immunohistochemistry: comparison of Davidson's solution and formalin as fixatives. *J Histochem Cytochem*. 2011;59:884–898.
2. Shaw G, Weber K. The structure and development of the rat retina: an immunofluorescence microscopical study using antibodies specific for intermediate filament proteins. *Eur J Cell Biol*. 1983;30:219–232.
3. Lai YL, Jacoby RO, Jonas AM. Age-related and light-associated retinal changes in Fischer rats. *Invest Ophthalmol Vis Sci*. 1978;17:634–638.
4. Anderson JR, Jones BW, Watt CB, et al. Exploring the retinal connectome. *Mol Vis*. 2011;17:355–379.
5. Bromberg JS, Schacner M. Localization of nervous system antigens in retina by immunohistology. *Invest Ophthalmol Vis Sci*. September 1978;17:920–924.
6. Ueda-Arakawa N, Ooto S, Ellabban AA, et al. Macular choroidal thickness and volume of eyes with reticular pseudodrusen using swept-source optical coherence tomography. *Am J Ophthalmol*. 2014;157:994–1004.
7. Sung KR, Kim DY, Park SB, Kook MS. Comparison of retinal nerve fiber layer thickness measured by Cirrus HD and Stratus optical coherence tomography. *Ophthalmology*. 2009;116:1264–1270.
8. Nag TC, Wadhwa S. Calbindin and parvalbuminimmunoreactivity in the developing and adult human retina. *Dev Brain Res*. 1996;93:23–32.
9. Sohn HE, Khanna A, Tucker BA, Abramoff MD, Stone EM, Mullins RF. Structural and biochemical analyses of choroidal thickness in human donor eyes. *Invest Ophthalmol Vis Sci*. 2014 Mar 6;55:1352–1360.
10. Garner S, Henkind P. Aging an degeneration of the human macula: I. Outer nuclear layer and photoreceptors. *Br J Ophthalmol*. 1981;65:23–28.
11. Cogan DG. Development and senescence of the human retinal vasculature. Doyne memorial lecture. *Trans Ophthalmol Soc U K*. 1963;83:465–491.
12. Gao H, Hollyfield JG. Aging of the human retina. *Invest Ophthalmol Vis Sci*. 1992;33:1–17.
13. Hsu SM, Raine L, Fanger H. Use of biotin-avidin peroxidase complex (ABC) in immunoperoxidase technique: a comparison between ABC and unlabeled antibody (PAP) procedures. *J Histochem Cytochem*. 1981;29:577–580.
14. Ross MH, Pawlina W, eds. *Histology a Text and Atlas: With Correlated Cell and Molecular Biology*. 6th ed. Philadelphia: Lippincott Williams & Wilkins; 2010.
15. Green WR. Chapter 9 retina. In: Spencer WH, ed. *Ophthalmic Pathology. An Atlas and Textbook*. 4th ed. Philadelphia, PA: W. B. Saunders, Co.; 1996:667–1331.
16. Friedman E, T'so MOM. The retinal pigment epithelium II. Histologic changes associated with age. *Arch Ophthalmol*. 1968;79:315–320.
17. Feeney L. Lipofuscin and melanin of human retinal pigment epithelium. Fluorescence, enzyme cytochemical, and ultrastructural studies. *Invest Ophthalmol Vis Sci*. 1978;17:583–600.
18. Bonilha VL. Age and disease-related structural changes in the retinal pigment epithelium. *Clin Ophthalmol*. 2008;2:413–424.
19. Aggarwal P, Nag TC, Wadhwa S. Age-related decrease in rod bipolar cell density of the human retina: an immune histochemical study. *J Biosci*. 2007;32:293–298.
20. Curcio CA, Millican CL, Allen KA, Kalina RE. Aging of the human photoreceptor mosaic: evidence for selective vulnerability of rods in central retina. *Invest Opthalmol Vis Sci*. 1993;34:3278–3296.
21. Del Viva MM, Agostini R. Visual spatial integration in the elderly. *Invest Ophthalmol Vis Sci*. 2007;48:2940–2946.
22. Lee JY, Hwang YH, Lee SM, Kim YY. Age and retinal nerve fibre layer thickness measured by spectral domain optical coherence tomography. *Korean J Ophthalmol*. 2012;26:163–168.
23. Celebi AR, Mirza GE. Age-related change in retinal nerve fiber layer thickness measured with spectral domain optical coherence tomography. *Invest Ophthalmol Vis Sci*. 2013;54:8095–8103.
24. Frenkel S, Morgan JE, Blumenthal EJ. Histological measurement of retinal nerve fibre layer thickness. *Eye*. 2005;19:491–498.