

Case Report

Empty fenestration of the external jugular vein: A rare variant



Satomi Sugiyama, Toshinori Iwai*, Iwai Tohnai

Department of Oral and Maxillofacial Surgery, Yokohama City University Graduate School of Medicine, 3-9 Fukuura, Kanazawa-ku, Yokohama, Kanagawa 236-0004, Japan

ARTICLE INFO

Article history:

Received 21 March 2017

Accepted 3 October 2017

Available online 10 October 2017

Keywords:

External jugular vein

Anatomical variation

Fenestration

ABSTRACT

The external jugular vein (EJV) is often utilized as a recipient vein in the head and neck during microsurgical reconstruction or for central venous catheterization. However, there are few studies about its anatomical variations. Knowledge of these variations is important for clinicians as well as surgeons. We report here an empty fenestration of the EJV, an extremely rare variant, observed during modified radical neck dissection.

© 2017 Anatomical Society of India. Published by Elsevier, a division of RELX India, Pvt. Ltd. All rights reserved.

1. Introduction

The external jugular vein (EJV) develops as a secondary channel from a capillary plexus derived from a tributary of the cephalic vein in the tissues of the neck. It anastomoses secondarily with the anterior facial vein and the cephalic vein forming a venous ring around the clavicle from where it connects with the caudal part of the precardinal veins.¹ Developmental errors during the crucial stages of venous formation result in abnormal venous patterns in particular venous channels.¹ Relatively few studies have investigated anatomical variations of the EJV compared with other vessels of the neck, although it is utilized as a recipient vein in the head and neck during microsurgical reconstruction or for central venous catheterization.^{1–3} However, knowledge of variations in the structure or course of the EJV is important for anesthesiologists or clinicians as well as surgeons. We report here an empty fenestration of the EJV, a rare variant, observed during modified radical neck dissection.

2. Case Report

A 77-year-old woman with cancer of the left side of the tongue (T3N1M0) underwent preoperative chemotherapy (docetaxel, cisplatin, and 5-fluorouracil) and irradiation (40 Gy). Six weeks after chemoradiotherapy, left hemi-glossectomy and modified radical neck dissection with microsurgical reconstruction were performed. During neck dissection, we found a fenestration of the EJV in the middle third. The vein then divided into medial and

lateral veins around the anterior border of the sternocleidomastoid muscle, and both veins united around the posterior border of the sternocleidomastoid muscle (Figs. 1 and 2). There was no nerve passing through the fenestration of the EJV.

3. Discussion

The EJV is usually formed by the union of the posterior division of the retromandibular and posterior auricular veins just below or inside the parotid gland, and then it joins the subclavian vein.¹ However, anatomical variations of the EJV, such as duplication, fenestration, or absence of the EJV, as well as anastomosis between the EJV and the internal jugular vein, have rarely been reported.^{1,2,4,5} “Duplication” consists of 2 veins that result from the division of a single trunk, each joining the subclavian vein separately. In the case of “fenestration” both trunks fuse again and rejoin the subclavian vein as a single vein.⁶ However, the terms “fenestration” and “duplication” are sometimes used interchangeably, and the variation of the EJV reported by Comert and Comert¹ was in fact a fenestration and not a duplication.

Because fenestration of the EJV is extremely rare, the incidence is uncertain. In our institution, among 250 neck dissections for patients with oral cancer between January 2004 and September 2016, only the present case had a fenestration of the EJV with an incidence of 0.4%. To our knowledge, only a few cases with fenestration of the EJV have been reported in the English-language literature (Table 1).^{1,2,4,5} We reviewed 5 cases including the present case. All patients were female, and there was no predominant side (right: 2 cases; left: 3 cases). The cervical branch of the facial nerve passed through the fenestration of the EJV in only 1 of the 5 cases. After division of the EJV around the anterior border of or on the sternocleidomastoid muscle, the EJV joined together around the

* Corresponding author.

E-mail address: iwai104oams@yahoo.co.jp (T. Iwai).

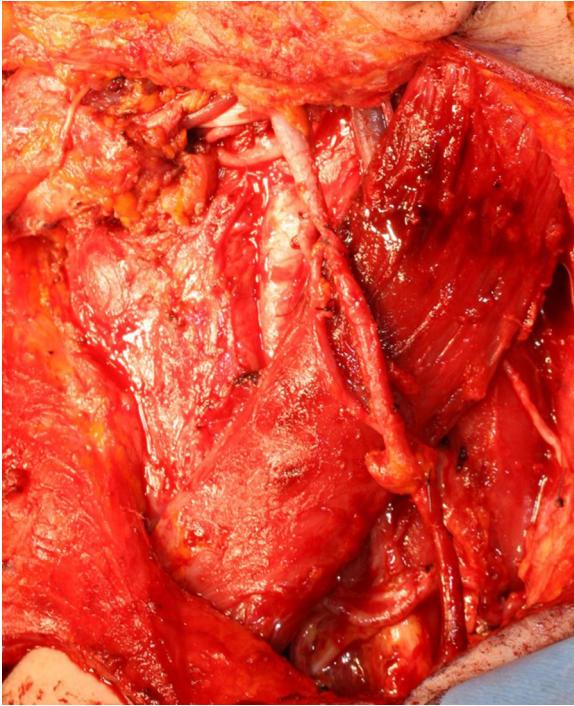


Fig. 1. Intraoperative view of the left external jugular vein (EJV). Fenestration of the EJV was found in the middle third. The EJV divided into medial and lateral veins near the anterior border of the sternocleidomastoid muscle, and both veins united near the posterior border of the sternocleidomastoid muscle.

posterior border of the sternocleidomastoid muscle in 4 of the 5 cases (80%). This finding was similar to type 2 of the classification by Shima et al. in which the veins joined around the posterior border of the sternocleidomastoid muscle (type 1 with single EJV: 83%; type 2: 17%).⁷

Preservation of the EJV in neck dissection reduces postoperative edema of the face and neck.^{8,9} Simultaneous bilateral radical neck dissection with ligation of both internal jugular veins may cause severe facial edema, papillary edema with blindness, intracranial hypertension, coma, and sometimes death.⁸ Furthermore, the EJV can be utilized for anastomosis in microsurgical reconstruction when sacrifice of the internal jugular vein is planned preoperatively. Therefore, the EJV should be preserved as much as possible when radical neck dissection is performed.

Surgeons and clinicians administering intravascular treatment or performing head and neck surgery including neck dissection or microsurgical reconstruction should be aware of this variation of the EJV to prevent inadvertent injury to the vessel.

Conflicts of interest

We have no conflicts of interest to declare.

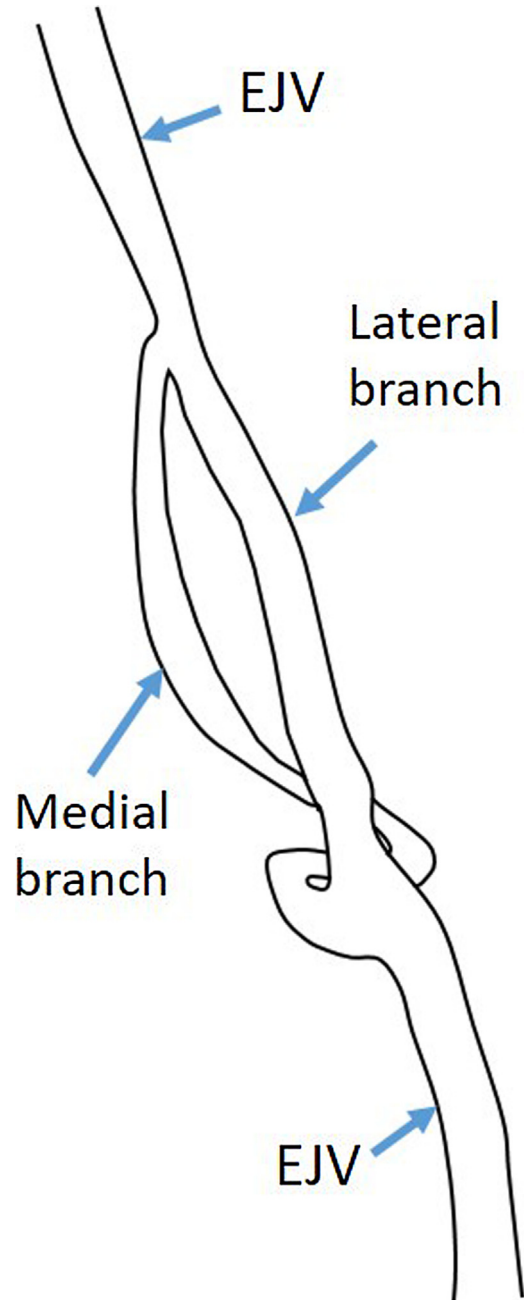


Fig. 2. Schema of the left external jugular vein (EJV).

Ethical approval and informed consent

Ethical approval was not required. Informed consent was obtained from the patient for being included in the study.

Table 1
Reported cases with the fenestration of the external jugular vein.

Author ^{Ref.} (Year)	Age	Sex	Side	Nerve passing through the fenestration of the EJV
Comert and Comert ¹ (2009)	47	F	R	None
Cvetko ⁵ (2013)	75	F	L	The cervical branch of the facial nerve
Snoj and Cvetko ² (2013)	77	F	L	None
Cvetko ⁴ (2015)	75	F	R	None
Present case	77	F	L	None

EJV, external jugular vein; F, female; L, left; M, male; R, right.

References

- [1]. Comert E, Comert A. External jugular vein duplication. *J Craniofac Surg.* 2009;20(6):2173–2174.
- [2]. Snoj Ž, Cvetko E. A case of unilateral fenestration and duplication of the external jugular vein. *Int J Morphol.* 2013;31(1):107–109.
- [3]. Nagata T, Masumoto K, Watanabe Y, Katou F. End-to-side anastomosis to the external jugular vein: preservation of external jugular vein blood flow. *Br J Oral Maxillofac Surg.* 2012;50(2):e31–e32.
- [4]. Cvetko E. A case of left-sided absence and right-sided fenestration of the external jugular vein and a review of the literature. *Surg Radiol Anat.* 2015;37(7):883–886.
- [5]. Cvetko E. A case of unilateral fenestration of the external jugular vein, through which the cervical branch of the facial nerve passes. *Anat Sci Int.* 2013;88(3):151–152.
- [6]. Downie SA, Schalop L, Mazurek JN, Savitch G, Lelonek GJ, Olson TR. Bilateral duplicated internal jugular veins: case study and literature review. *Clin Anat.* 2007;20(3):260–266.
- [7]. Shima H, von Luedinghausen M, Ohno K, Michi K. Anatomy of microvascular anastomosis in the neck. *Plast Reconstr Surg.* 1998;101(1):33–41.
- [8]. da Rocha RL, Del Negro A, Tincani AJ, Del Negro MS, Martins AS. Preservation of the external jugular vein in bilateral radical neck dissections: technique in two cases and review of the literature. *Case Rep Med.* 2015;2015:168474.
- [9]. Chung MK, Choi J, Lee JK, Jeong JI, Lee WY, Jeong HS. Preservation of the external jugular venous drainage system in neck dissection. *Otolaryngol Head Neck Surg.* 2009;141(6):730–736.